ARTICLE | Article in Press

Effects of bonded rapid maxillary expansion and miniscrew-assisted rapid palatal expansion on craniocervical posture, sagittal pharyngeal airway dimensions, and hyoid bone position

Esra Tuhan Kutlu · Baris Baser

Received: 11 June 2026 / Accepted: 23 October 2026
© The Author(s) 2026

Abstract

This study aimed to compare the effects of bonded rapid maxillary expansion (RME) and miniscrew-assisted rapid palatal expansion (MARPE) on skeletal measurements, craniocervical posture, sagittal pharyngeal airway dimensions, and hyoid bone position using lateral cephalometric radiographs. This retrospective cohort study included 60 patients with transverse maxillary deficiency treated with bonded RME or MARPE. The bonded RME group included 30 patients (17 females and 13 males) and the MARPE group included 30 patients (16 females and 14 males). Lateral cephalometric radiographs obtained before treatment (T0) and 6 months after completion of active screw activation (T1) were analyzed using ImageJ software. Generalized estimating equation models were used for repeated-measures comparisons, and chronological age was included as a covariate. After adjustment for age, no significant group × time interaction was observed for any skeletal measurement. ANB showed a significant time effect, whereas SNA, SNB, SN–GoGn, NSL/NL, and FH/ML did not show significant time-dependent changes. No significant group, time, or group × time interaction effects were detected for sagittal pharyngeal airway or hyoid measurements. Significant group × time interactions were observed for NSL/OPT, NSL/CVT, and CVT/HOR, indicating different craniocervical postural change patterns between the groups. In skeletal Class I patients with transverse maxillary deficiency and normal vertical growth patterns, bonded RME and MARPE showed comparable skeletal, sagittal pharyngeal airway, and hyoid outcomes after age adjustment. The absence of significant sagittal airway and hyoid changes should be interpreted within the limits of two-dimensional cephalometric assessment. The craniocervical posture findings should be considered exploratory and interpreted cautiously.

Keywords Rapid maxillary expansion · miniscrew-assisted rapid palatal expansion · craniocervical posture · sagittal pharyngeal airway · hyoid bone position

Abbreviations

RME	Rapid maxillary expansion
MARPE	Miniscrew-assisted rapid palatal expansion

This Article in Press is shared early to give you faster access to new research. It is citable and carries a permanent DOI. The final edited version will replace it automatically.



https://doi.org/10.1038/s41598-026-77964-x

Published online: 07 November 2026

SARME	Surgically assisted rapid palatal expansion
T0	Before treatment
T1	Six months after completion of active screw activation
CVM	Cervical vertebral maturation
GEE	Generalized estimating equations
ICC	Intraclass correlation coefficient
NHP	Natural head position
CBCT	Cone-beam computed tomography

Background

Maxillomandibular transverse discrepancy is a common orthodontic problem, often presenting as unilateral or bilateral posterior crossbite[1,2]. Its etiology is complex and may include genetic, functional, respiratory, habitual, and pathological factors[3].

Maxillary expansion is commonly used to manage transverse maxillary deficiency. Although rapid maxillary expansion (RME) can open the midpalatal suture, conventional tooth-borne appliances may produce unwanted dentoalveolar effects, such as posterior tooth tipping, periodontal changes, and root resorption[4–7]. Miniscrew-assisted rapid palatal expansion (MARPE) was therefore developed to improve skeletal anchorage and direct expansion forces more effectively to the basal bone[8,9].

Transverse maxillary deficiency may also be associated with alterations in nasal and upper airway morphology[10,11]. A constricted maxillary arch may reduce nasal cavity width and contribute to increased nasal airway resistance, which can influence respiratory function, orofacial muscle posture, and craniocervical orientation[12]. In response to increased airway resistance, changes in head and cervical posture, including a tendency toward head extension, have been suggested as adaptive mechanisms to help maintain airway patency[13,14].

Previous studies have reported that RME may increase transverse maxillary dimensions and modify nasal cavity morphology, while also producing changes in occlusal relationships, vertical dimension, mandibular posture, and tongue position[15,16]. Because the mandible, tongue, and hyoid bone are anatomically and functionally connected through the suprahyoid and infrahyoid musculature, such skeletal and functional changes may be accompanied by secondary changes in hyoid bone position[14].

Bonded RME and MARPE differ in their biomechanical characteristics, anchorage design, and occlusal coverage. Bonded RME is a tooth-borne expansion appliance that typically includes posterior acrylic occlusal coverage, which has been described as functioning similarly to a bite block and may influence vertical dimension and mandibular posture[17].

In contrast, MARPE was developed to increase the skeletal effects of expansion and reduce undesirable dentoalveolar effects by incorporating miniscrew anchorage. Hybrid tooth–bone-borne MARPE appliances are supported by both palatal miniscrews and dental anchorage, such as molar bands, allowing expansion forces to be transmitted more directly to the maxillary basal bone while still involving the dentition[18]. These differences may partly explain why bonded RME and MARPE could produce different craniocervical, airway-related, or hyoid responses.

Although previous studies have evaluated the effects of maxillary expansion on airway dimensions, hyoid bone position, and head posture, the evidence remains inconsistent, particularly regarding whether these changes are clinically meaningful and whether they differ according to appliance design[19,20]. Most available studies have focused on conventional tooth-borne expansion protocols, whereas comparative data on bonded RME and MARPE remain limited[9].

In addition, the interpretation of airway-related findings differs according to the imaging method used. Lateral cephalometry allows standardized assessment of sagittal pharyngeal airway dimensions and their relationship

with craniofacial and craniocervical structures; however, it does not provide volumetric information about the airway. Therefore, cephalometric airway changes should be interpreted as two-dimensional sagittal measurements rather than as direct evidence of volumetric or functional airway improvement.

Therefore, this retrospective cohort study aimed to compare the effects of bonded RME and MARPE on skeletal measurements, craniocervical posture, sagittal pharyngeal airway dimensions, and hyoid bone position using lateral cephalometric radiographs.

Materials and methods

This study was designed as a retrospective cohort study based on the evaluation of existing clinical and radiographic records. Ethical approval was obtained from the Ethics Committee of the Faculty of Dentistry, Karadeniz Technical University (Approval No. 2025/29; June 23, 2025).

A power analysis was performed using G*Power software (v3.1.9.2) to determine the required sample size. Because of the retrospective design, a formally registered or prospectively prespecified primary outcome was not available. Craniocervical posture measurements were the main outcome domain of interest for sample size estimation. The analysis was based on the between-group difference in the EVT/VER variable reported by Serritella et al.[5]. The calculated effect size was d = 0.598. With an alpha level of 0.05 and 80% power, the minimum required sample size was calculated as 24 patients per group, for a total of 48 patients. A total of 60 patients with complete clinical and radiographic records were included. The MARPE group comprised 30 patients (16 females and 14 males), and the bonded RME group comprised 30 patients (17 females and 13 males).

Patients who met the following inclusion criteria were enrolled in the study: skeletal Class I malocclusion ($0° < ANB \leq 4°$), normal vertical growth pattern ($26° < SN–GoGn < 38°$), presence of posterior crossbite associated with transverse maxillary deficiency, treatment with bonded RME or MARPE, and availability of baseline and follow-up cephalometric radiographs. Patients with systemic diseases or psychosocial disorders, a history of craniofacial anomalies or trauma involving the head region, previous orthodontic treatment, allergic rhinitis, or adenoid hypertrophy were excluded from the study. However, other factors that may influence natural head position, such as breathing pattern, muscle tone, visual balance, occlusal status, and individual postural habits, were not quantitatively assessed and were therefore considered unmeasured confounders.

Skeletal maturation was assessed using the cervical vertebral maturation (CVM) method, and only patients at CS3 or CS4 were included to reduce heterogeneity related to skeletal maturation. This criterion was selected to allow comparison of the two expansion protocols within a similar pubertal or post-pubertal growth period.

The study sample consisted of patients treated for transverse maxillary deficiency using either bonded RME or MARPE. In the bonded RME group, a bonded rapid maxillary expander was used (Leone Orthodontic Products, Sesto Fiorentino, Firenze, Italy) (Fig. 1). The appliance consisted of a rigid acrylic splint covering the buccal, occlusal, and palatal surfaces of the posterior teeth. The expansion screw was positioned parallel to the palate, close to the deepest and most central region of the palatal vault.

In the MARPE group, a hybrid tooth–bone-borne miniscrew-assisted rapid palatal expander was used. The appliance was a Maxillary Skeletal Expander (MSE; BioMaterials Korea, Inc.), as introduced by Dr. Won Moon. It was supported by four palatal miniscrews and first molar bands, providing both skeletal and dental anchorage. The miniscrews were 1.8 mm in diameter and 11 mm in length. Depending on palatal width, 8-mm or 10-mm MSE expansion screws were used. The appliance body was positioned as posteriorly as possible, near the junction of the hard and soft palate, to facilitate a more parallel opening pattern of the midpalatal suture (Fig. 2).

The activation regimen was the same in both groups and consisted of twice-daily screw activation, with each turn corresponding to 0.2 mm. Active expansion was continued until a clinically satisfactory maxillomandibular transverse relationship was achieved according to the individual treatment plan. Therefore, the total activation amount and activation duration varied slightly among patients and were calculated from the clinical records.

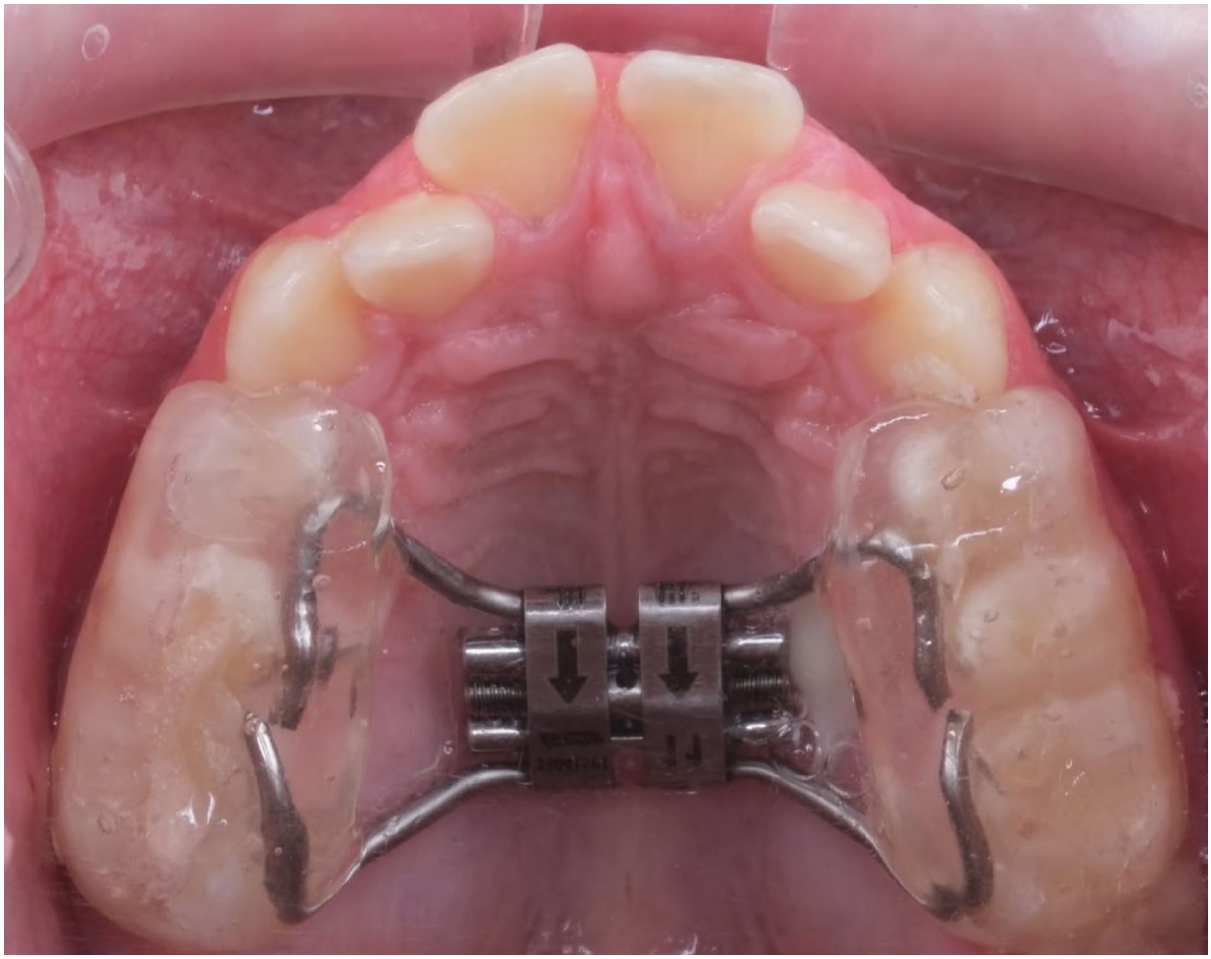

Fig. 1 Bonded RME appliance with bilateral posterior acrylic coverage and midpalatal expansion screw.

Representative occlusal photographs showing the opened expansion screws are presented in Figs. 3 and 4 to illustrate the clinical activation of the bonded RME and MARPE appliances, respectively.

Radiographic evaluation

All lateral cephalometric radiographs were obtained using the same device, a Carestream CS 9300 Digital Panoramic and Cephalometric System (Carestream Health, Inc., Rochester, NY, USA), by the same radiology technician according to the manufacturer's standardized imaging protocol. During image acquisition, patients were positioned upright in the cephalostat, with the midsagittal plane perpendicular to the floor and parallel to the image receptor. Radiographs were acquired in natural head position using the mirror technique. Patients were instructed to look at their own eyes in a mirror placed in front of them, with the teeth in centric occlusion and the lips at rest. No attempt was made to orient the Frankfort horizontal plane parallel to the floor.

Skeletal, craniocervical posture, airway, and hyoid measurements were evaluated on lateral cephalometric radiographs at two time points (T0 and T1) using ImageJ software. T0 corresponded to the pretreatment stage, and T1 was defined as 6 months after completion of active screw activation. This interval was selected to allow post-expansion stabilization and to evaluate short-term changes after the retention period, in accordance with previous studies using 6-month retention or post-expansion evaluation protocols[21,22]. After active expansion, the appliances were kept in place passively during the retention period. The total T0–T1 interval was calculated for

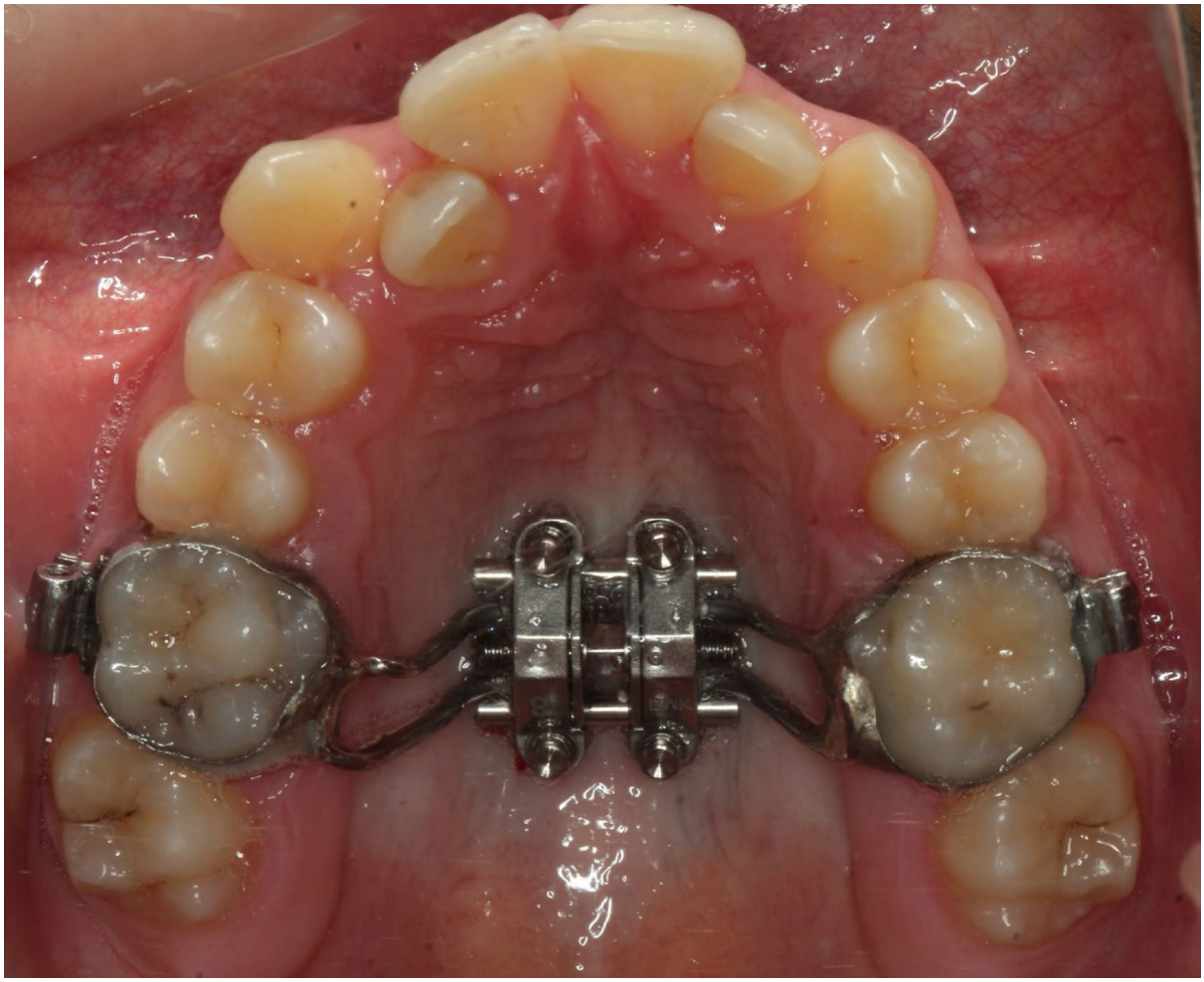

Fig. 2 MARPE appliance with four palatal miniscrews, first molar bands, and midpalatal expansion screw.

each patient and compared between the groups. The definitions of the anatomical landmarks and reference lines used for the cephalometric measurements are provided in Tables 1 and 2, and the measurements are illustrated in Figs. 5 and 6. All measurements were performed by a single calibrated examiner blinded to group allocation and time points, according to previously described methods[23,24]. To assess intra-observer reliability, 20 randomly selected radiographs were re-evaluated by the same examiner after a 2-week interval, and intraclass correlation coefficients were calculated.

Statistical analysis

Statistical analyses were performed using IBM SPSS Statistics version 23.0. Because the study included repeated measurements obtained from the same participants, generalized estimating equations (GEE) were used for the statistical analysis. Participant identification number was included in the model as the subject variable to account for the dependency between repeated measurements, and an exchangeable working correlation matrix was specified.

The statistical model included the main effects of group and time, as well as the two-way group × time interaction. Chronological age was also included as a covariate to control for its potential confounding effect. When significant main effects or interaction effects were detected, pairwise comparisons were performed using estimated marginal means to identify the source of the differences. Bonferroni correction was applied to control for Type I error in pairwise comparisons.

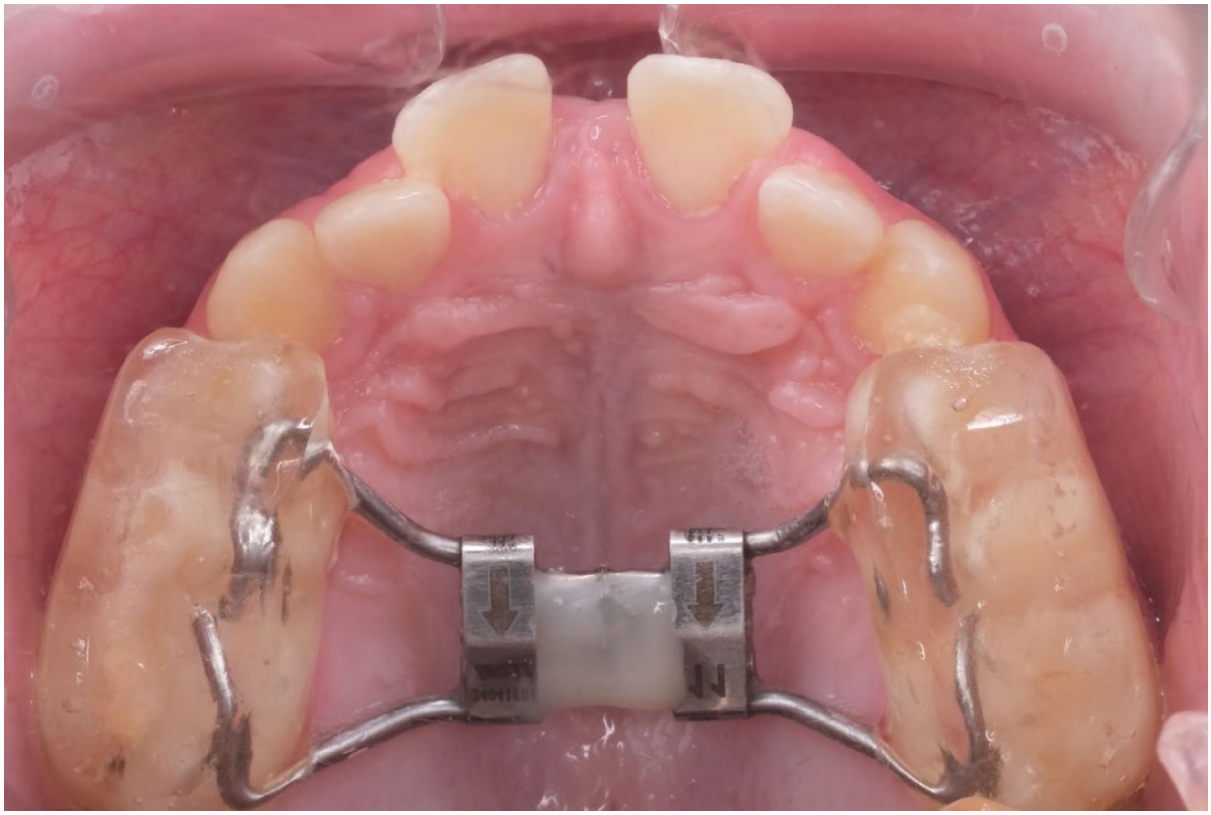

Fig. 3 Representative occlusal photograph showing the opened expansion screw after active activation of the bonded RME appliance.

For comparisons of non-normally distributed continuous variables between two independent groups, the Mann–Whitney U test was used. Associations between categorical variables were evaluated using Pearson's chi-square test with Yates' continuity correction. Quantitative data were presented as mean ± standard deviation or median (minimum–maximum), as appropriate. Categorical data were presented as frequency and percentage. The level of statistical significance was set at $p < 0.05$.

Results

Intra-observer reliability analysis showed acceptable to excellent agreement for all repeated measurements, with intraclass correlation coefficient (ICC) values ranging from 0.752 to 0.994. Detailed ICC values are provided in Supplementary Table 1.

Baseline and treatment-related characteristics of the study groups are presented in Table 3. The MARPE group was significantly older than the bonded RME group ($p < 0.001$). Total activation amount and activation duration were also significantly higher in the MARPE group ($p = 0.002$ for both); however, the absolute differences between groups were small. The total T0–T1 interval was comparable between the groups ($p = 0.626$). No significant differences were observed between the groups in terms of cervical vertebral maturation stage or sex distribution.

After adjustment for age, no significant group × time interaction was observed for any skeletal measurement, indicating that the skeletal changes from T0 to T1 did not differ significantly between the bonded RME and MARPE groups. A significant time effect was found for ANB ($p < 0.001$), whereas no significant time effect was

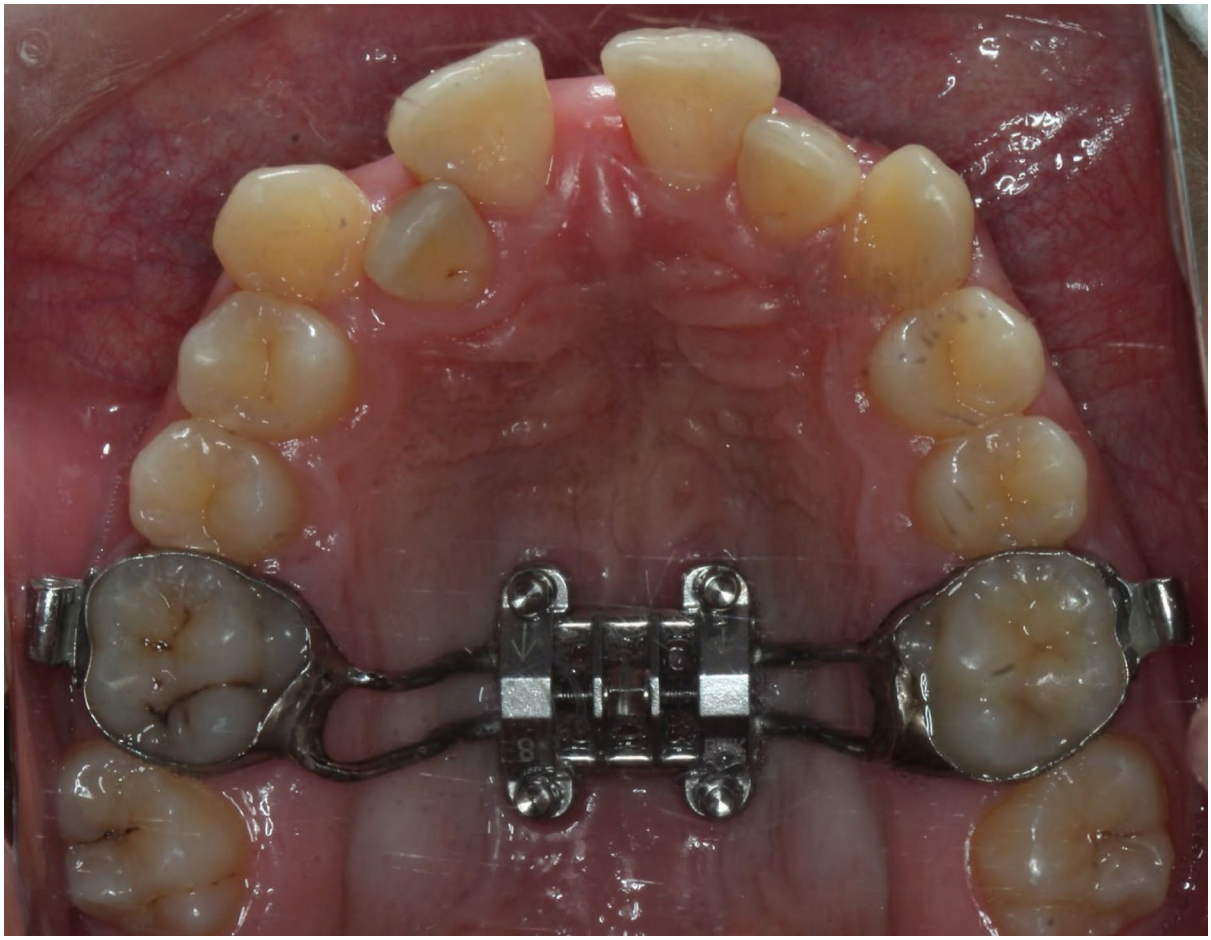

Fig. 4 Representative occlusal photograph showing the opened expansion screw after active activation of the MARPE appliance.

observed for SNA, SNB, SN–GoGn, NSL/NL, or FH/ML. Chronological age was a significant covariate for SNA and SN–GoGn.

Craniocervical posture measurements after adjustment for age are presented in Table 4. Significant group × time interactions were observed for NSL/OPT ($p=0.004$), NSL/CVT ($p<0.001$), and CVT/HOR ($p=0.038$), indicating that the pattern of change over time differed between the bonded RME and MARPE groups for these variables. No significant group × time interactions were found for NSL/VER, NL/VER, NL/OPT, NL/CVT, OPT/HOR, or OPT/CVT. Chronological age was not a significant covariate for any craniocervical posture measurement.

After adjustment for age, no significant group, time, or group × time interaction effects were observed for sagittal pharyngeal airway measurements. PNS–UPW, CV2′–MPW, CV3′–LPW, U–PNS, and HRL/U–PNS did not show significant differences between groups or significant changes over time. Chronological age was a significant covariate only for U–PNS (Tables 5, 6).

Hyoid bone measurements after adjustment for age are presented in Table 7. No significant group, time, or group × time interaction effects were detected for H–CV2, H–CV3, H⊥NSL, or H⊥ML. Chronological age was not a significant covariate for any hyoid measurement. These findings indicate that hyoid bone position did not differ significantly between the bonded RME and MARPE groups and did not show a significant overall change from T0 to T1.

Overall, after adjustment for age, bonded RME and MARPE showed comparable skeletal, sagittal pharyngeal airway, and hyoid outcomes. However, significant group × time interactions were observed for selected

Table 1 Definitions of cephalometric landmarks.

Landmark	Definition
S	Sella; the center of the sella turcica
N	Nasion; the most anterior point of the frontonasal suture
Po	Porion; the uppermost point of the external auditory meatus
Or	Orbitale; the lowest point on the inferior margin of the orbit
A	Point A; the deepest point on the anterior contour of the maxillary alveolar process
B	Point B; the deepest point on the anterior contour of the mandibular symphysis.
Go	Gonion; the most posterior-inferior point at the angle of the mandible
Gn	Gnathion; the most anterior-inferior point on the mandibular symphysis
ANS	Anterior nasal spine; the most anterior point of the maxilla at the base of the nasal cavity
PNS	Posterior nasal spine; the most posterior point of the hard palate
Ptm	Pterygomaxillary fissure; the most posterior-superior point of the pterygomaxillary fissure
U	Uvula point; the tip of the soft palate
UPW	Upper pharyngeal wall; the point where the extension of the ANS–PNS line intersects the posterior pharyngeal wall
MPW	Middle pharyngeal wall; the point where the CV2 line, defined as the line passing through CV2 and parallel to the horizontal reference plane, intersects the posterior pharyngeal wall
LPW	Lower pharyngeal wall; the point where the CV3 line, defined as the line passing through CV3 and parallel to the horizontal reference plane, intersects the posterior pharyngeal wall
CV2′	The point where the CV2 line, defined as the line passing through CV2 and parallel to the horizontal reference plane, intersects the anterior pharyngeal wall
CV3′	The point where the CV3 line, defined as the line passing through CV3 and parallel to the horizontal reference plane, intersects the anterior pharyngeal wall
Cv2tg	The most superior-posterior point on the odontoid process of the second cervical vertebra
Cv2ip	The most inferior-posterior point on the body of the second cervical vertebra
Cv4ip	The most inferior-posterior point on the body of the fourth cervical vertebra
Cv2	The most anterior-inferior point on the body of the second cervical vertebra
Cv3	The most anterior-inferior point on the body of the third cervical vertebra
H	Hyoid point; the most superior-anterior point on the body of the hyoid bone

Table 2 Definitions of reference lines and planes

Reference plane	Definition
NSL	Sella–nasion line; the line connecting S and N
NL	Nasal line; the line connecting ANS and Ptm depending on the measurement protocol used
FH	Frankfort horizontal plane; the line connecting Po and Or
ML/MP	Mandibular plane; the line connecting Go and Gn
HOR	Horizontal reference line; the true horizontal reference line used in natural head position
VER	Vertical reference line; the true vertical reference line perpendicular to HOR
OPT	Odontoid process tangent; the line connecting Cv2tg and Cv2ip
CVT	Cervical vertebral tangent; the line connecting Cv2tg and Cv4ip

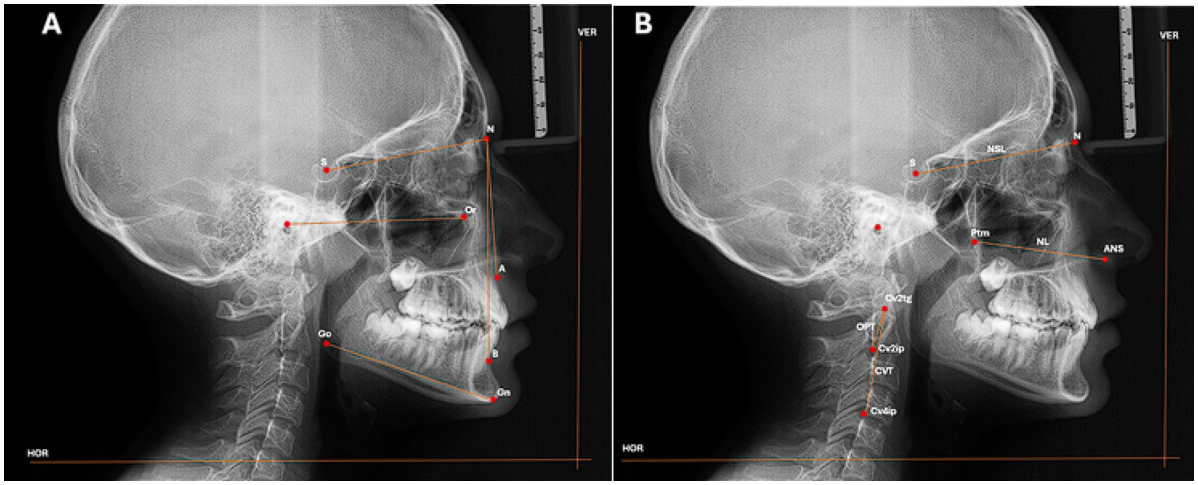

Fig. 5 Representative lateral cephalometric radiographs illustrating skeletal and craniocervical posture measurements. (**A**) Skeletal landmarks and reference planes used for angular measurements. (**B**) Craniocervical posture measurements. Landmark and reference line definitions are provided in Tables 1 and 2.

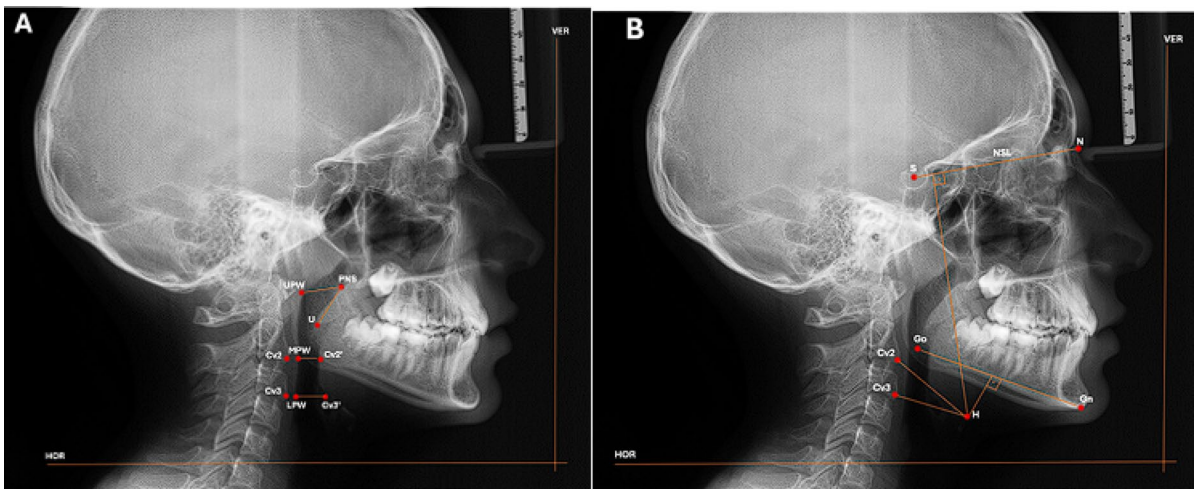

Fig. 6 Representative lateral cephalometric radiographs illustrating pharyngeal airway and hyoid measurements. (**A**) Pharyngeal airway measurements. (**B**) Hyoid bone measurements. Landmark and reference line definitions are provided in Tables 1 and 2.

craniocervical posture variables, indicating that the pattern of change over time differed between the two expansion protocols.

Discussion

In the present study, the effects of bonded RME and MARPE on skeletal measurements, craniocervical posture, sagittal pharyngeal airway dimensions, and hyoid bone position were compared using lateral cephalometric radiographs. Because chronological age differed significantly between the groups, the analyses were adjusted for age. After age adjustment, both treatment approaches showed comparable skeletal, sagittal pharyngeal airway, and hyoid outcomes. However, significant group × time interactions were observed for NSL/OPT, NSL/CVT, and

Table 3 Baseline and treatment-related characteristics of the study groups.

Variable	Bonded RME	MARPE	*p*-value
Age, years	12.00 (11.00–14.00)	15.00 (13.00–17.00)	< 0.001
Total activation amount, mm	5.60 (5.20–6.40)	6.00 (5.20–6.40)	0.002
Activation duration, days	14.00 (13.00–16.00)	15.00 (13.00–16.00)	0.002
Total T0–T1 interval, months	6.64 (6.00–7.33)	6.67 (6.13–7.50)	0.626
Cervical vertebral maturation stage			0.505
CS3	26 (86.7)	23 (76.7)	
CS4	4 (13.3)	7 (23.3)	
Sex			1.000
Female	17 (56.7)	16 (53.3)	
Male	13 (43.3)	14 (46.7)	

Continuous variables are presented as median (minimum–maximum), and categorical variables are presented as n (%). The Mann–Whitney U test was used for continuous variables, and Pearson's chi-square test with Yates' continuity correction was used for categorical variables. A *p*-value < 0.05 was considered statistically significant.

Table 4 Comparison of skeletal measurements according to group and time after adjustment for age

Variable	Time	Bonded RME	MARPE	Group *p*	Time *p*	Group × Time *p*	Age *p*
SNA (°)	T0	79.79 ± 2.90	79.96 ± 3.27	0.245	0.800	0.119	**0.049**
	T1	80.17 ± 3.22	79.68 ± 3.14				
SNB (°)	T0	77.08 ± 2.76	77.01 ± 3.15	0.459	0.071	0.696	0.202
	T1	76.76 ± 3.07	76.52 ± 3.59				
ANB (°)	T0	2.76 ± 0.99	2.95 ± 0.98	0.234	**< 0.001**	0.090	0.084
	T1	3.51 ± 1.35	3.27 ± 1.33				
SN-GoGn (°)	T0	35.39 ± 2.97	34.81 ± 3.21	0.145	0.180	0.788	**0.031**
	T1	35.74 ± 3.72	35.34 ± 4.72				
NSL/NL (°)	T0	18.22 ± 3.99	20.18 ± 3.80	0.032	0.881	0.680	0.825
	T1	18.34 ± 3.17	19.92 ± 3.89				
FH/ML (°)	T0	27.86 ± 4.83	26.94 ± 5.14	0.621	0.431	0.293	0.083
	T1	28.77 ± 5.59	26.81 ± 5.17				

Data are presented as mean ± standard deviation. Generalized estimating equation models were used. Chronological age was included as a covariate in the model. The group effect indicates the overall difference between the bonded RME and MARPE groups, the time effect indicates the overall change from T0 to T1, and the group × time interaction indicates whether the pattern of change over time differed between groups. A *p*-value < 0.05 was considered statistically significant.

Significant values are in [bold].

CVT/HOR, indicating that the pattern of change over time differed between the groups for these craniocervical posture parameters.

Skeletal effects should be interpreted in relation to the expected biomechanical responses of the two expansion protocols. Conventional tooth-borne or bonded RME has been associated with transverse skeletal expansion accompanied by variable sagittal and vertical changes, including slight forward or downward displacement of the maxilla, changes in ANB, and mandibular plane opening due to transient occlusal interference or posterior mandibular rotation[15,25]. Chung and Font reported small but significant increases in SNA and ANB, downward movement of ANS and PNS, and an increase in MP–SN after rapid palatal expansion, suggesting that part of the sagittal change may be related to vertical maxillary displacement and mandibular rotation rather than pure sagittal advancement[15].

In contrast, MARPE is expected to produce greater skeletal anchorage and relatively less dentoalveolar tipping than conventional tooth-borne RME[6,21,26]. Recent systematic review evidence suggests that MARPE may produce statistically significant but clinically modest sagittal skeletal changes, including small increases in SNA and ANB, while vertical skeletal dimensions tend to remain relatively stable[26,27]. Therefore, although MARPE may provide more skeletal expansion in the transverse dimension, its sagittal and vertical cephalometric effects are not necessarily large or clinically relevant.

Table 5 Comparison of craniocervical posture measurements according to group and time after adjustment for age.

Variable	Time	Bonded RME	MARPE	Group *p*	Time *p*	Group × Time *p*	Age *p*
NSL/VER (°)	T0	82.46±3.48	81.96±5.24	0.521	0.649	0.054	0.901
	T1	81.04±3.56	82.84±4.82				
NL/VER (°)	T0	79.32±4.23	77.71±6.10	0.084	0.695	0.200	0.908
	T1	80.53±4.55	77.07±6.08				
NSL/OPT (°)	T0	63.80±6.89	59.85±8.94	0.387	0.806	**0.004**	0.837
	T1	61.24±7.60	62.00±9.43				
NL/OPT (°)	T0	80.63±5.94	78.01±6.19	0.997	0.812	0.070	0.443
	T1	79.02±7.30	79.25±7.14				
NSL/CVT (°)	T0	69.23±8.16	64.62±8.34	0.242	0.166	**<0.001**	0.488
	T1	65.58±7.64	66.24±9.17				
NL/CVT (°)	T0	82.83±5.29	81.81±4.79	0.889	0.158	0.694	0.638
	T1	81.87±5.97	81.26±4.83				
OPT/HOR (°)	T0	71.30±7.15	67.71±8.40	0.187	0.961	0.168	0.767
	T1	70.11±6.83	68.99±7.31				
CVT/HOR (°)	T0	76.77±8.36	72.48±8.50	0.114	0.286	**0.038**	0.369
	T1	74.45±6.67	73.23±7.17				
OPT/CVT (°)	T0	5.44±2.99	5.31±3.23	0.385	0.077	0.802	0.341
	T1	4.75±2.85	4.79±3.89				

Data are presented as mean±standard deviation. Generalized estimating equation models were used. Chronological age was included as a covariate in the model. The group effect indicates the overall difference between the bonded RME and MARPE groups, the time effect indicates the overall change from T0 to T1, and the group × time interaction indicates whether the pattern of change over time differed between groups. A *p*-value < 0.05 was considered statistically significant.

Significant values are in [bold].

Table 6 Comparison of pharyngeal airway measurements according to group and time after adjustment for age.

Variable	Time	Bonded RME	MARPE	Group *p*	Time *p*	Group × Time *p*	Age *p*
PNS–UPW (mm)	T0	18.04±6.60	20.35±3.64	0.416	0.618	0.628	0.624
	T1	18.65±4.41	20.36±3.96				
CV2′–MPW (mm)	T0	10.76±3.90	11.27±4.56	0.686	0.349	0.763	0.464
	T1	10.50±3.07	10.76±3.04				
CV3′–LPW (mm)	T0	11.37±3.87	13.15±4.73	0.785	0.749	0.492	0.327
	T1	11.57±3.48	12.60±3.51				
U–PNS (mm)	T0	25.28±7.53	26.43±4.17	0.356	0.560	0.776	**0.016**
	T1	25.48±5.08	27.01±4.94				
HRL/U–PNS (°)	T0	49.43±8.07	50.70±8.50	0.117	0.968	0.518	0.253
	T1	48.85±7.86	51.36±5.66				

Data are presented as mean±standard deviation. Generalized estimating equation models were used. Chronological age was included as a covariate in the model. The group effect indicates the overall difference between the bonded RME and MARPE groups, the time effect indicates the overall change from T0 to T1, and the group × time interaction indicates whether the pattern of change over time differed between groups. A *p*-value < 0.05 was considered statistically significant.

Significant values are in [bold].

After adjustment for age, no significant group × time interaction was observed for any skeletal measurement, indicating that skeletal changes from T0 to T1 were comparable between bonded RME and MARPE. SNA and SNB did not show significant time-dependent changes, suggesting that neither protocol produced a marked sagittal skeletal effect during the observation period. Although ANB showed a significant time effect, this change should be interpreted cautiously, as it may reflect minor changes in sagittal maxillomandibular relationship related to dentoalveolar adaptation, mandibular position, or growth rather than a protocol-specific treatment effect[15,26,28,29]. Unlike some previous studies reporting increased vertical skeletal dimensions after RME, SN–GoGn did not show a significant time effect after age adjustment in the present study[25,30].

Table 7 Comparison of hyoid measurements according to group and time after adjustment for age.

Variable	Time	Bonded RME	MARPE	Group *p*	Time *p*	Group × Time *p*	Age *p*
H–CV2 (mm)	T0	38.08 ± 7.15	38.94 ± 5.57	0.763	0.379	0.060	0.433
	T1	36.55 ± 4.22	39.49 ± 6.13				
H–CV3 (mm)	T0	33.21 ± 4.33	36.58 ± 4.57	0.110	0.330	0.514	0.275
	T1	32.46 ± 2.52	36.44 ± 4.39				
H⊥NSL (mm)	T0	99.39 ± 15.76	100.39 ± 10.13	0.809	0.840	0.367	0.734
	T1	98.10 ± 8.45	101.21 ± 10.74				
H⊥ML (mm)	T0	17.48 ± 5.87	16.14 ± 5.02	0.515	0.170	0.611	0.801
	T1	17.03 ± 3.88	15.16 ± 4.01				

Data are presented as mean ± standard deviation. Generalized estimating equation models were used. Chronological age was included as a covariate in the model. The group effect indicates the overall difference between the bonded RME and MARPE groups, the time effect indicates the overall change from T0 to T1, and the group × time interaction indicates whether the pattern of change over time differed between groups. A p-value < 0.05 was considered statistically significant.

In the present study, after adjustment for age, significant group × time interactions were observed for NSL/OPT, NSL/CVT, and CVT/HOR. These findings indicate that the pattern of craniocervical postural change over time differed between the bonded RME and MARPE groups for these variables. In general, NSL/OPT, NSL/CVT, and CVT/HOR values tended to decrease in the bonded RME group, whereas they tended to increase in the MARPE group. However, these opposite-direction trends should be interpreted cautiously. A significant interaction indicates a difference in the pattern of change over time between groups, but it does not by itself confirm a specific neuromuscular or postural mechanism. In addition, post hoc comparisons did not consistently localize all interaction effects. Therefore, these findings should be considered exploratory and hypothesis-generating rather than confirmatory.

Previous studies have suggested that craniocervical posture may change mildly after maxillary expansion, possibly in relation to changes in airway patency, occlusal contacts, vertical dimension, or mandibular posture[5,12,23,24,31]. Tecco et al.[32] reported that improvement in nasopharyngeal airway adequacy after RME was accompanied by head flexion and reduced craniocervical angulation. However, in the present study, no significant group, time, or group × time interaction effects were observed for sagittal pharyngeal airway measurements after age adjustment. Therefore, the observed craniocervical posture interactions should not be interpreted as a direct consequence of pharyngeal airway enlargement.

The different postural change patterns observed between bonded RME and MARPE may potentially be related to appliance-related biomechanical differences. The bonded RME appliance included posterior acrylic occlusal coverage, which may temporarily influence occlusal vertical dimension, mandibular posture, and cervical orientation independently of the transverse expansion effect. In contrast, MARPE used a hybrid tooth–bone-borne anchorage design with palatal miniscrews and molar bands, which may produce different skeletal and dentoalveolar force distribution. Nevertheless, because functional respiratory tests, electromyographic assessment, and objective postural evaluations were not performed, the mechanisms underlying the craniocervical findings cannot be determined from the present data.

In the present study, no significant group, time, or group × time interaction effects were observed for sagittal pharyngeal airway measurements after adjustment for age. Although maxillary expansion has been reported to increase nasal cavity width and reduce nasal airway resistance[33,34], airway responses may depend on the baseline site of obstruction, transverse deficiency severity, and the biomechanical characteristics of the expansion protocol[33]. Conventional tooth-borne RME generally produces a more triangular opening pattern with greater anterior than posterior skeletal effects[35], whereas MARPE protocols, especially when positioned more posteriorly, have been suggested to produce a relatively more parallel midpalatal suture opening pattern[36]. These differences may influence the regional distribution of skeletal expansion and its potential effect on the nasal airway.

However, because the present study used lateral cephalometric radiographs, transverse nasal cavity changes, volumetric airway alterations, and functional airway outcomes could not be evaluated. This limitation is important

because recent three-dimensional studies and systematic reviews have reported variable airway findings after RME and MARPE. Niu et al.[10] reported that the available evidence mainly supports a short-term increase in nasal cavity volume and the upper part of the upper airway after RME, whereas the long-term stability and clinical relevance of these changes remain less certain. Similarly, a recent CBCT-based review on bone-borne and miniscrew-assisted expansion suggested that MARPE-related protocols may increase nasal and nasopharyngeal airway dimensions, but emphasized that the predictability and clinical durability of these airway benefits remain uncertain[37].

Therefore, the absence of significant sagittal pharyngeal airway changes in the present study should be interpreted as a finding limited to two-dimensional sagittal cephalometric measurements and should not be considered evidence of equivalent volumetric or functional airway effects between bonded RME and MARPE.

After adjustment for age, no significant group, time, or group × time interaction effects were observed for any hyoid measurement, including H–CV2, H–CV3, H⊥NSL, and H⊥ML. These findings indicate that neither bonded RME nor MARPE produced a detectable change in hyoid bone position during the observation period, and the pattern of change did not differ significantly between the two protocols.

The absence of significant hyoid changes may be related to both the skeletal findings and the characteristics of the study population. In the present study, no significant group × time interaction was observed for sagittal or vertical skeletal measurements, and SN–GoGn did not show a significant time effect after age adjustment. Therefore, neither protocol appeared to produce a differential sagittal or vertical skeletal response that could clearly explain secondary hyoid repositioning. This interpretation is supported by previous studies reporting limited or variable hyoid responses after maxillary expansion. Shetty et al.[38] reported no significant change in hyoid position after RME using CBCT, despite changes in airway-related structures, while Schmid et al.[39] found that hyoid bone position remained generally stable after SARME and that changes were not clearly associated with appliance type or amount of expansion. Moreover, the present cohort consisted of skeletal Class I patients with normal vertical growth patterns, and patients with allergic rhinitis or adenoid hypertrophy were excluded. Taken together, these findings suggest that hyoid position may be influenced more by individual craniofacial morphology, mandibular posture, tongue posture, and baseline functional airway status than by maxillary expansion alone.

This study has several limitations. First, because of the retrospective cohort design, treatment allocation was not randomized. The choice of bonded RME or MARPE was based on clinical indications, including chronological age, skeletal maturation, anchorage requirements, transverse maxillary deficiency, and the clinician's treatment planning decision. Therefore, selection bias and confounding by indication cannot be excluded. Although chronological age was included as a covariate and CVM stage distribution was comparable between groups, residual age- or growth-related confounding may still have influenced the findings.

Second, although the sample size exceeded the minimum required by the power analysis, larger prospective studies are needed to improve generalizability and to allow subgroup analyses. In addition, because a formally registered or prospectively prespecified primary outcome was not available, and multiple skeletal, sagittal airway, hyoid, and craniocervical variables were analyzed, the findings should be interpreted with caution.

Third, no untreated control group was included; therefore, the possible effects of growth on craniofacial morphology, sagittal pharyngeal airway dimensions, hyoid bone position, and craniocervical posture cannot be completely separated from treatment-related changes. The severity of transverse maxillary deficiency was also not quantitatively analyzed, because standardized baseline transverse measurements were not consistently available for all patients.

Another limitation is that the pharyngeal airway was evaluated using two-dimensional lateral cephalometric radiographs. Although this method allows routine sagittal airway and craniocervical assessment, it does not provide volumetric or functional airway information, such as nasal resistance, airflow, breathing pattern, or sleep-related respiratory status.

Finally, head posture may be influenced by breathing pattern, muscle tone, visual balance, occlusal status, and individual postural habits, which were not quantitatively assessed. In addition, because the bonded RME appliance included posterior acrylic occlusal coverage and was retained passively after active expansion, continued

occlusal coverage may have temporarily influenced occlusal vertical dimension, mandibular posture, and craniocervical orientation. Future prospective studies with matched or randomized designs, standardized transverse measurements, three-dimensional airway evaluation, and functional respiratory and postural assessments are needed.

Conclusion

After adjustment for chronological age, bonded RME and MARPE showed comparable skeletal, sagittal pharyngeal airway, and hyoid outcomes in skeletal Class I patients with transverse maxillary deficiency and normal vertical growth patterns. No significant sagittal pharyngeal airway or hyoid changes were detected using lateral cephalometric radiographs, suggesting that appliance selection in similar patients should not be based solely on the expectation of sagittal airway or hyoid improvement.

Significant group × time interactions were observed for NSL/OPT, NSL/CVT, and CVT/HOR, indicating different patterns of craniocervical postural change between the two expansion protocols. However, these findings should be interpreted cautiously and considered exploratory because of the retrospective design, non-randomized treatment allocation, age differences between groups, unmeasured functional factors, and the two-dimensional nature of the airway assessment. Further prospective studies with matched samples, standardized transverse measurements, three-dimensional airway imaging, and functional respiratory and postural evaluations are needed.

Supplementary Information The online version contains supplementary material available at https://doi.org/10.1038/s41598-026-77964-x.

Acknowledgements Not applicable.

Author contributions ETK and BB contributed to the conception and design of the study, methodology, investigation, data curation, validation, and interpretation of the data. ETK and BB were involved in drafting the manuscript, critical revision, and final editing. Both authors read and approved the final manuscript.

Funding This research received no external funding.

Data availability The data supporting the findings of this study are available from the corresponding author upon reasonable request. Due to ethical and privacy restrictions related to patient data, the data are not publicly available.

Declarations

Competing interests The authors declare no competing interests.

Ethics approval and consent to participate This study was conducted in accordance with the ethical principles of the Declaration of Helsinki. Ethical approval was obtained from the Ethics Committee of the Faculty of Dentistry, Karadeniz Technical University (Approval No. 2025/29; June 23, 2025).

Informed consent Because of the retrospective nature of the study, the requirement for informed consent was waived by the ethics committee.

Open Access This article is licensed under a Creative Commons Attribution-NonCommercial-NoDerivatives 4.0 International License, which permits any non-commercial use, sharing, distribution and reproduction in any medium or format, as long as you give appropriate credit to the original author(s) and the source, provide a link to the Creative Commons licence, and indicate if you modified the licensed material. You do not have permission under this licence to share adapted material derived from this article or parts of it. The images or other third party material in this article are included in the article's Creative Commons licence, unless indicated otherwise in a credit line to the material. If material is not included in the article's Creative Commons licence and your intended use is not permitted by statutory regulation or exceeds the permitted use, you

will need to obtain permission directly from the copyright holder. To view a copy of this licence, visit http://creativecommons.org/licenses/by-nc-nd/4.0/.

References

1. Empson, I. et al. Short- and long-term effects of conventional and miniscrew-assisted rapid palatal expansion on hard tissues using voxel-based superimposition of serial cone-beam computed tomography scans. *Am. J. Orthod. Dentofac. Orthop.***166** (5), 445–457e2. https://doi.org/10.1016/j.ajodo.2024.06.017 (2024).
2. Malandris, M. & Mahoney, E. K. Aetiology, diagnosis and treatment of posterior cross-bites in the primary dentition. *Int. J. Paediatr. Dent.***14** (3), 155–166. https://doi.org/10.1111/j.1365-263X.2004.00546.x (2004).
3. Ugolini, A., Agostino, P., Silvestrini-Biavati, A., Harrison, J. E. & Batista, K. B. Orthodontic treatment for posterior crossbites. *Cochrane Database Syst. Rev.***12** (12), CD000979. https://doi.org/10.1002/14651858.CD000979.pub3 (2021).
4. Barton, B. et al. Long-term assessment of skeletal and dental asymmetry after conventional and mini-implant-assisted rapid palatal expansion. *Am. J. Orthod. Dentofac. Orthop.***167** (4), 399–408e1. https://doi.org/10.1016/j.ajodo.2024.10.018 (2025).
5. Serritella, E., Impellizzeri, A., Musone, L., De Stefano, A. A. & Gabriella, G. Cranio-cervical posture and rapid palatal expansion therapy. *J. Orthod. Sci.***11** (1), 13. https://doi.org/10.4103/jos.jos_128_21 (2022).
6. Mehta, S., Arqub, S. A., Vishwanath, M., Upadhyay, M. & Yadav, S. Biomechanics of conventional and miniscrew-assisted rapid palatal expansion. *J. World Fed. Orthod.***13** (3), 105–112 https://doi.org/10.1016/j.ejwf.2024.03.002 (2024).
7. Kumar, M., Goyal, M., Singh, T. & Shaha, K. Questions regarding long-term effects on the alveolar bone with bone-anchored and tooth-anchored rapid palatal expansion. *Am. J. Orthod. Dentofac. Orthop.***162** (6), 803. https://doi.org/10.1016/j.ajodo.2022.08.020 (2022).
8. Lee, K. J., Park, Y. C., Park, J. Y. & Hwang, W. S. Miniscrew-assisted nonsurgical palatal expansion before orthognathic surgery for a patient with severe mandibular prognathism. *Am. J. Orthod. Dentofac. Orthop.***137** (6), 830–839. https://doi.org/10.1016/j.ajodo.2007.10.065 (2010).
9. Abu Arqub, S. et al. Does Mini Screw Assisted Rapid Palatal Expansion (MARPE) have an influence on airway and breathing in middle-aged children and adolescents? A systematic review. *Int. Orthod.***19** (1), 37–50. https://doi.org/10.1016/j.ortho.2021.01.004 (2021).
10. Niu, X., Di Carlo, G., Cornelis, M. A. & Cattaneo, P. M. Three-dimensional analyses of short- and long-term effects of rapid maxillary expansion on nasal cavity and upper airway: A systematic review and meta-analysis. *Orthod. Craniofac. Res.***23** (3), 250–276. https://doi.org/10.1111/ocr.12378 (2020).
11. Gianoni-Capenakas, S., Horta, K. C., Flores-Mir, C., Lagravère, M. O. & Pacheco-Pereira, C. Rapid maxillary expansion effects on the upper airway dimensions and function in growing patients: An umbrella review. *J. Dent. Sleep. Med.* **7** (4). https://doi.org/10.15331/jdsm.7164 (2020).
12. Carbajal-Rodriguez, G. et al. Effects of rapid maxillary expansion on head and cervical posture in growing patients: A systematic review. *Int. Orthod.***20** (3), 100658. https://doi.org/10.1016/j.ortho.2022.100658 (2022).
13. Sabatucci, A. et al. Breathing pattern and head posture: changes in craniocervical angles. *Minerva Stomatol.* **64** (2), 59–74 (2015).
14. Phoenix, A., Valiathan, M., Nelson, S., Strohl, K. P. & Hans, M. Changes in hyoid bone position following rapid maxillary expansion in adolescents. *Angle Orthod.* **81** (4), 632–638. https://doi.org/10.2319/060710-313.1 (2011).
15. Chung, C. H. & Font, B. Skeletal and dental changes in the sagittal, vertical, and transverse dimensions after rapid palatal expansion. *Am. J. Orthod. Dentofac. Orthop.* **126** (5), 569–575. https://doi.org/10.1016/j.ajodo.2003.10.035 (2004).
16. Ozbek, M. M., Memikoglu, U. T. T., Altug-Atac, A. T. & Lowe, A. A. Stability of maxillary expansion and tongue posture. *Angle Orthod.* **79** (2), 214–220. https://doi.org/10.2319/010908-12.1 (2009).
17. Horne, S. et al. Effects of bonded rapid palatal expander on vertical dimension: A systematic review and meta-analysis. *J. Clin. Med.* **14** (19), 7035. https://doi.org/10.3390/jcm14197035 (2025).
18. Labunet, A., Iosif, C., Kui, A., Vigu, A. & Sava, S. Miniscrew-assisted rapid palatal expansion: A scoping review of influencing factors, side effects, and soft tissue alterations. *Biomedicines* **12** (11), 2438. https://doi.org/10.3390/biomedicines12112438 (2024).
19. Buck, L. M., Dalci, O., Darendeliler, M. A., Papageorgiou, S. N. & Papadopoulou, A. K. Volumetric upper airway changes after rapid maxillary expansion: A systematic review and meta-analysis. *Eur. J. Orthod.* https://doi.org/10.1093/ejo/cjw048 (2016). cjw048.
20. Bucci, R. et al. Effects of maxillary expansion on the upper airways: Evidence from systematic reviews and meta-analyses. *J. Oral Rehabil*. **46** (4), 377–387. https://doi.org/10.1111/joor.12766 (2019).

21. Yung, A. K. C. et al. Comparative three dimensional evaluation of skeletal and dento-alveolar effects between tooth-borne and bone-anchored maxillary expansion for growing patients—A systematic review and meta-analysis. *Orthod. Craniofac. Res.* **28** (6), 907–928. https://doi.org/10.1111/ocr.70029 (2025).
22. Costa, J. G., Galindo, T. M., Mattos, C. T. & Cury-Saramago, A. A. Retention period after treatment of posterior crossbite with maxillary expansion: A systematic review. *Dent. Press. J. Orthod.* **22** (2), 35–44. https://doi.org/10.1590/2177-6709.22.2.035-044.oar (2017).
23. Çoban, G., Öztürk, T., Erdem, M. E., Kış, H. C. & Yağcı, A. Effects of maxillary expansion and protraction on pharyngeal airway dimensions in relation to changes in head posture and hyoid position. *J. Orofac. Orthop./Fortschr. der Kieferorthopädie*. **84** (S3), 172–185. https://doi.org/10.1007/s00056-022-00426-2 (2023).
24. Solow, B. Cranio-cervical posture: A factor in the development and function of the dentofacial structures. *Eur. J. Orthod.* **24** (5), 447–456. https://doi.org/10.1093/ejo/24.5.447 (2002).
25. Farronato, G., Giannini, L., Galbiati, G. & Maspero, C. Sagittal and vertical effects of rapid maxillary expansion in Class I, II, and III occlusions. *Angle Orthod.* **81** (2), 298–303. https://doi.org/10.2319/050410-241.1 (2011).
26. Huang, X., Han, Y. & Yang, S. Effect and stability of miniscrew-assisted rapid palatal expansion: A systematic review and meta-analysis. *Korean J. Orthod.* **52** (5), 334–344. https://doi.org/10.4041/kjod21.324 (2022).
27. Xie, B., Zhang, L. & Lu, Y. Skeletal effects after miniscrew-assisted rapid palatal expansion on sagittal and vertical dimensions: A systematic review and meta-analysis. *Int. Dent. J.* **76** (5), 109779. https://doi.org/10.1016/j.identj.2026.109779 (2026).
28. Oliveira, T. F. M., Pereira-Filho, V. A., Gabrielli, M. F. R., Gonçales, E. S. & Santos-Pinto, A. Effects of surgically assisted rapid maxillary expansion on mandibular position: A three-dimensional study. *Prog. Orthod.* **18** (1), 22. https://doi.org/10.1186/s40510-017-0179-8 (2017).
29. Kotarska, M. et al. Changes in the mandible following rapid maxillary expansion in children with class II malocclusion: A systematic review. *Diagnostics (Basel)*. **12** (7). https://doi.org/10.3390/diagnostics12071688 (2022).
30. Chhutani, P. et al. Effect of rapid maxillary expansion on mandibular rotation—A systematic review. *J. Indian Orthodontic Soc.* **54** (1), 5–13. https://doi.org/10.1177/0301574219897318 (2020).
31. Yagci, A., Uysal, T., Usumez, S. & Orhan, M. Rapid maxillary expansion effects on dynamic measurement of natural head position. *Angle Orthod.* **81** (5), 850–855. https://doi.org/10.2319/112410-686.1 (2011).
32. Tecco, S., Festa, F., Tete, S., Longhi, V. & D'Attilio, M. Changes in head posture after rapid maxillary expansion in mouth-breathing girls: A controlled study. *Angle Orthod.* **75** (2), 171–176 (2005).
33. Basciftci, F. A., Mutlu, N., Karaman, A. I., Malkoc, S. & Küçükkolbasi, H. Does the timing and method of rapid maxillary expansion have an effect on the changes in nasal dimensions? *Angle Orthod.* **72** (2), 118–123 (2002).
34. Wertz, R. A. Changes in nasal airflow incident to rapid maxillary expansion. *Angle Orthod.* **38** (1), 1–11 (1968).
35. Garrett, B. J. et al. Skeletal effects to the maxilla after rapid maxillary expansion assessed with cone-beam computed tomography. *Am. J. Orthod. Dentofac. Orthop.* **134** (1), 8–9 https://doi.org/10.1016/j.ajodo.2008.06.004 (2008).
36. Cantarella, D. et al. Changes in the midpalatal and pterygopalatine sutures induced by micro-implant-supported skeletal expander, analyzed with a novel 3D method based on CBCT imaging. *Prog Orthod.* **18** (1), 34. https://doi.org/10.1186/s40510-017-0188-7 (2017).
37. Al-Madani, N. N. et al. Impact of bone-borne and miniscrew-assisted rapid palatal expansion on airway dimensions and postexpansion stability: Evidence from cone-beam CT studies. Cureus. **6** (2025). https://doi.org/10.7759/cureus.98578
38. Shetty, N., Nambiar, S., Desai, A. & Ahmed, J. Effect of maxillary expansion treatment protocols on maxillary sinus volume, pharyngeal airway volume, and hyoid bone position: A prospective, cone beam computed tomography (CBCT) Study. *Open. Dent. J.* **16** (1). https://doi.org/10.2174/18742106-v16-e2208220 (2022).
39. Schmid, J. Q. et al. Hyoid bone position with bone-borne or tooth-borne surgically assisted rapid palatal expansion: A retrospective cohort study. *Clin. Oral Investig*. **29** (11), 526. https://doi.org/10.1007/s00784-025-06529-5 (2025).

Publisher's note Springer Nature remains neutral with regard to jurisdictional claims in published maps and institutional affiliations.

Authors and Affiliations

Esra Tuhan Kutlu[1] · Baris Baser[1]

✉ Esra Tuhan Kutlu
esratuhan@gmail.com

[1] Department of Orthodontics, Faculty of Dentistry, Karadeniz Technical University, 61080 Trabzon, Turkey