Human Reproduction, Vol.26, No.3 pp. 564–568, 2011
Advanced Access publication on January 17, 2011 doi:10.1093/humrep/deq378

human reproduction

ORIGINAL ARTICLE *Gynaecology*

Acute increase in plasma D-dimer level in ovarian torsion: an experimental study

Cavit Kart[1], Turhan Aran[1], Suleyman Guven[1,*], S. Caner Karahan[2], and Esin Yulug[3]

[1]Department of Obstetrics and Gynecology, School of Medicine, Karadeniz Technical University, Trabzon, Turkey [2]Department of Biochemistry, School of Medicine, Karadeniz Technical University, Trabzon, Turkey [3]Department of Histology and Embryology, School of Medicine, Karadeniz Technical University, Trabzon, Turkey

*Correspondence address. Suleyman Guven, KTÜ Tıp Fakültesi, Farabi Hastanesi Kadın Hastalıkları ve Doğum ABD, 61080 Trabzon, Turkey. Tel: +90-462-377-58-69; Fax: +90-462-325-05-18; E-mail: drsuleymanguven@yahoo.com

Submitted on September 26, 2010; resubmitted on November 30, 2010; accepted on December 7, 2010

BACKGROUND: Torsion of the ovary is a rare but serious cause of gynecologic surgical emergency. Specific laboratory markers that support the preoperative diagnosis of ovarian torsion are not currently available in the clinical routine. The aim of this study was to investigate the diagnostic value of plasma D-dimer level as an early indicator of ovarian torsion in an experimental rat ovarian torsion model.

METHODS: Sixteen female adult Sprague–Dawley rats were used for this controlled experimental study. Eight rats in the sham operation group (Group I) underwent a surgical procedure similar to Group II but the ovary was not occluded. In Group II (eight rats), a torsion model was created by using atraumatic vascular clips just above and below the right ovary for a 2-h period of ischemia. Right ovaries were surgically removed at the end of the procedure in each group. Blood was sampled before and after operation to assess plasma D-dimer levels. The main outcome measure was ovarian histopathologic findings scores and plasma D-dimer levels.

RESULTS: There was no significant difference in pre-operative plasma D-dimer levels (0.5963 ± 0.2047 mg/l in Group I, 0.6344 ± 0.1348 mg/l in Group II, $P = 0.815$, Mann–Whitney *U*-test). However, mean plasma D-dimer value for Group II was significantly higher than that in the control group (1.2267 ± 0.3099 versus 0.6213 ± 0.2346 mg/l, respectively, Mann–Whitney *U*-test, $P < 0.001$), following 2 h of ovarian torsion. Ovarian tissue damage scores were also statistically significantly different among groups.

CONCLUSIONS: If the observations made in a rat model are extended to humans, plasma D-dimer measurement may be a valuable parameter in the early diagnosis of ovarian torsion.

Key words: biochemical marker / ovarian torsion / D-dimer / diagnostic parameter

Introduction

Torsion of the ovary is a rare but serious cause of gynecologic surgical emergency with a prevalence of 2.7% (Hibbard, 1985). Rapid diagnosis and surgical treatment are the keys to preserve fertility and salvage the twisted ovary. However, the clinical diagnosis of ovarian torsion usually relies only on non-specific clinical signs, which delay the diagnosis, such as the presence of abdominal pain and ultrasonographic finding of an adnexal mass. But a worrying fact is that most (56%) of the patients treated by an urgent diagnostic laparoscopy do not have a confirmed ovarian torsion (Cohen *et al.*, 2001). Specific laboratory markers that support the preoperative diagnosis of ovarian torsion are not available in the clinical routine today. A statistically significant association between the diagnosis of ovarian torsion and interleukin-6 (IL-6) in peripheral blood was demonstrated previously (Cohen *et al.*, 2001; Daponte *et al.*, 2006). Additionally, in the rat ovarian torsion model, ischemia-modified albumin (IMA) was found to be associated with torsion response (Aran *et al.*, 2010).

The use of D-dimer levels as an indicator of intestinal ischemia has gained wide popularity following the publication of a number of studies indicating the potential useful role of D-dimer levels indiagnosis of venous thromboembolic disorders in all body organs, including the lungs, upper extremities, pelvis, thigh and calf (Acosta *et al.*, 2004). A similar pathophysiology could be expected in ovarian torsion in which there were firstly venous and lately arterial thrombotic vessels in the twisted pedicle and the ischemic ovary (Hibbard, 1985). To the best of our knowledge, there is no such study reporting the diagnostic value of D-dimer in ovarian torsion.

© The Author 2011. Published by Oxford University Press on behalf of the European Society of Human Reproduction and Embryology. All rights reserved.
For Permissions, please email: journals.permissions@oup.com

Downloaded from https://academic.oup.com/humrep/article-abstract/26/3/564/2914139 by Karadeniz Teknik University Library (KTU) user on 08 June 2020

The aim of this experimental study was, therefore, to investigate the effect of ovarian torsion on plasma D-dimer levels and to determine whether D-dimer levels were a useful adjunct that could be used in the diagnosis of ovarian torsion.

Materials and Methods

Animals and study design

A total of 16 female adult Sprague–Dawley rats weighing 150–220 g were obtained from the Karadeniz Technical University's Experimental Animal Laboratory. The animals were kept under standard laboratory conditions at a controlled temperature of 20–22°C, humidity of 55–60% and controlled photoperiod of 12:12 h light:dark. They were provided with a standard laboratory diet, free access to food and water, and were housed at the Animal Research Center of Karadeniz Technical University. The study protocol was reviewed and approved by Karadeniz Technical University Ethics Committee for animal research.

Randomization

To randomly allocate the animals into groups, all rats were initially randomly numbered. Then, computer-assisted randomization was utilized according to the instructions at www.randomization.com. The study team was blind to the randomized groups, at least until the randomization was carried out, while the investigators responsible for the biochemical and histological studies were all blind to the randomized groups until the end of the study. Rats were allocated randomly to Group I (control) or Group II (ovarian torsion model) on the day of the experiment.

Anesthesia and surgical technique

Each rat was weighed and anesthetized with intraperitoneal ketamine hydrochloride (50 mg/kg Ketalar; Eczacibasi, Istanbul, Turkey) and xylazin hydrochloride (10 mg/kg Rompun; Bayer, Leverkusen, Germany), which were repeated as it is necessary to maintain anesthesia throughout the experiments. They were allowed to breath spontaneously (not intubated) during the study. The animals were oxygenated with an oxygen mask, through which flowed a volume of 1–1.5 l/min in the first part of the procedure and throughout the experiment, but oxygen saturation was not monitored.

Rats were placed in the dorsal recumbent position and covered with sterile drapes during surgery. A 1-ml preoperative blood sample was drawn from the tail of each rat to determine basal plasma levels of D-dimer. Then, the skin area of the incision was shaved and disinfected. A longitudinal incision of 2 cm was performed in the midline area of the lower abdomen for laparotomy, and the uterine horns and adnexa were located. In Group I (control group, sham-operated group), the abdominal wall was kept open for 1 min and then closed with 3/0 silk sutures. In Group II, a torsion model was created by using atraumatic vascular clips just above and below the right ovary. Incision was closed with 3/0 silk sutures. In both groups, 2 h after the first operation, re-laparotomy was performed through the previous incision sites. A 1-ml blood sample was taken again from the tail of each rat to determine the effect of the sham operation (Group I) and torsion operation (Group II) on plasma D-dimer level. After blood samples had been taken, the right ovary was surgically removed.

Histologic examination

The ovarian tissues were fixed in 10% neutral buffered formalin solution for 48 h, dehydrated, cleared and embedded in paraffin as usual. Serial tissue sections at a thickness of 5 μm were cut using the microtome and stained with hematoxylin and eosin (H&E) for general morphological observation. All sections were investigated with a light microscope (Olympus BX-51; Olympus Optical Co., Ltd., Tokyo, Japan) and the pieces were photographed. At least five microscopic areas were examined to semi quantitatively score the specimens. The criteria for ovarian injury were follicular cell degeneration, vascular congestion, hemorrhage and infiltration by inflammatory cells. Each specimen was scored for each criterion, using a scale ranging from 0 to 3 (0: none; 1: mild; 2: moderate; 3: severe) (Guven *et al.*, 2010). The ovary sections were analyzed in a blinded fashion by the same histologist.

D-dimer measurement

Blood samples collected in citrated tubes were centrifuged for 15 min at 1000 rpm at room temperature. Plasma levels of D-dimer in separated were quantified using an immuno-turbidimetric assay (STA Liatest D-dimer, Diagnostica Stago, Asniéres-sur-Seine, France) on the STA-R coagulation analyzer. STA-Liatest D-dimer is a latex-based immunoassay obtained from Diagnostica Stago. The assay was performed using the STA-R equipment from Diagnostica Stago. The detection limit of this assay is 0.22 mg/l of D-dimer. STA-Liatest D-dimer assay was expressed in milligrams per liter of fibrinogen equivalent units, and the intra- and inter-assay coefficients of variation were 3.0 and 3.8%, respectively. The time required to have D-dimer result available for clinical decision-making is almost 40 min by using immuno-turbidimetric assay on the STA-R coagulation analyzer (manufacturer data).

Statistical analysis

The Statistical Package Program for the Social Sciences (SPSS 11.0; SPSS Inc., Chicago, IL, USA) was used for statistical analysis. Data normality were assessed with the Kolmogorov–Smirnov test. Statistical comparisons between groups were performed using the Mann–Whitney *U* (for unrelated samples) and Wilcoxon (for related samples) tests. The correlation coefficient was determined by the Pearson test. All *P*-values were two-tailed and statistical significance was set at $P < 0.05$.

Results

The mean body-weights of rats in Groups I (190.00 ± 12.25 g) and II (193.75 ± 28.25 g) were comparable ($P = 0.743$, Mann–Whitney *U*-test). There was no significant difference in pre-operative plasma D-dimer levels (0.5963 ± 0.2047 mg/l in Group I, 0.6344 ± 0.1348 mg/l in Group II, $P = 0.815$, Mann–Whitney *U*-test). However, mean plasma D-dimer value for Group II was significantly higher than that in the control group (1.2267 ± 0.3099 versus 0.6213 ± 0.2346 mg/l, respectively, Mann–Whitney *U*-test, $P < 0.001$), following 2 h of ovarian torsion.

A comparison of individual point for post-operative plasma D-dimer level in each group is given in Fig. 1.

There was a significant increase in the plasma D-dimer value in Group II [$P = 0.008$, Wilcoxon test (including baseline values)], while no significant change was observed in Group I [$P = 0.528$, Wilcoxon test (including baseline values)] during the experiment. Compared with Group I (mean difference from the baseline +0.0250 ± 0.2660 mg/l), ovarian torsion significantly increased the plasma levels of D-dimer in Group II (mean difference from the baseline +0.5922 ± 0.3001 mg/l). The comparison was also statistically significant ($P < 0.001$, Mann–Whitney *U*-test).

A comparison of histopathological examination scores is shown in Fig. 2. Compared with Group I, in Group II, histologic specimens of the ovary had higher scores for follicular cell degeneration, vascular

Downloaded from https://academic.oup.com/humrep/article-abstract/26/3/564/2914139 by Karadeniz Teknik University Library (KTU) user on 08 June 2020

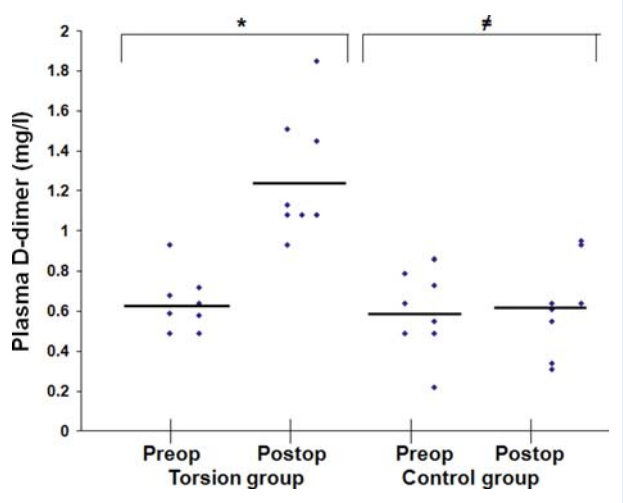

Figure 1 Individual plasma D-dimer values pre- and post-op, along with group means (horizontal line) ($^{*}P < 0.05$, $^{\#}P > 0.05$).

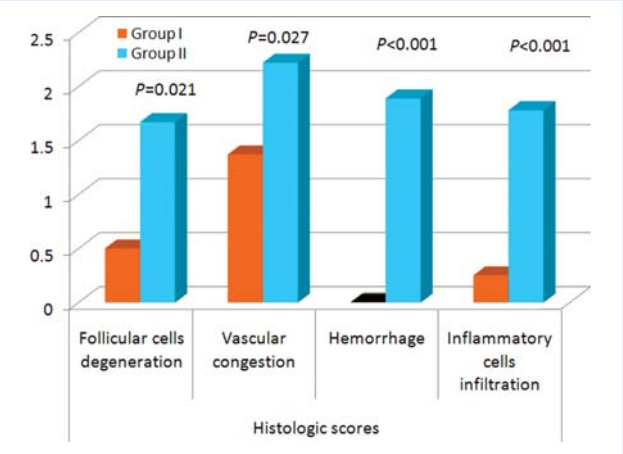

Figure 2 Histopathologic score results of Groups I and II (Mean values are given).

congestion, hemorrhage and inflammatory cell infiltration. As shown in Fig. 3a–c, compared with the control group, in the ovarian torsion group, severe follicular cell degeneration, vascular congestion, hemorrhage and inflammatory cell infiltration were observed. The mean histopathologic score (the summary score of four ovarian injury parameters) was significantly higher in Group II than in Group I (7.6 ± 2.2 versus 2.1 ± 1.0, respectively, Mann–Whitney *U*-test, $P = 0.001$).

Bivariate analysis revealed that post-operative plasma D-dimer level was well correlated with the summary score of four ovarian injury parameters ($r = 0.633$, $P = 0.006$).

Discussion

In this study, D-dimer, which reflects the extent of fibrin turnover, was studied as a possible marker for ovarian torsion. Our results demonstrate that plasma D-dimer levels appear to be elevated in ovarian torsion and may be useful in the early diagnosis and management of such surgical emergency conditions.

The diagnosis of ovarian torsion is usually done under urgent conditions of the gynecological emergency room. Moreover, several other gynecological and non-gynecological pathologies must be excluded. Urgent laparoscopy is considered the gold standard for accurate diagnosis. Thus many gynecologists elect to perform an urgent diagnostic laparoscopy rather than to delay the definite diagnostic procedure. But a worrying fact is that most (56%) of the patients treated by an urgent diagnostic laparoscopy do not have a confirmed ovarian torsion. The risk associated with urgent laparoscopy, often undertaken during the night, especially when performed by inexperienced personnel, may be increased. It is well known that under such urgent conditions, the rate of complications is increased (Cohen *et al.*, 2001). A simple and more precise test in the sera may assist in making the diagnosis. If this test is found to be accurate, then patients may benefit from a justified urgent laparoscopy due to ovarian torsion rather than risk damage to the ovary following conservative observation. Additional imaging modalities may further delay the decision to operate and are not always helpful (Pena *et al.*, 2000).

Serum IL-6, IL-8, tumor necrosis factor-alpha (TNF-a) and E-selectin have been investigated as serum markers in patients with ovarian torsion (Cohen *et al.*, 2001; Daponte *et al.*, 2006). A mouse model of myocardial ischemia reperfusion indicated that IL-6 was significantly elevated during the reperfusion phase (Hirano *et al.*, 1990). A similar mechanism might exist in ovarian torsion, and it was previously reported, in eight patients, that a significant association between IL-6, but not TNF-a, and diagnosis of ovarian torsion (Cohen *et al.*, 2001) exists. It has also been found that patients with serum IL-6 values >10.2 pg/ml had a 16 times higher risk of having ovarian torsion (Daponte *et al.*, 2006). Estimation of serum IL-6 level in a female patient with vague clinical signs of possible ovarian torsion such as adnexal mass and acute abdominal pain could help in differentiating patients, who would benefit from emergency surgical intervention, from others who could be treated conservatively. Among situations investigated and treated surgically, IL-6 was also associated with intestinal ischemia or endometrioma and appendicitis (Daponte *et al.*, 2006). Additionally, in a recently published well-designed experimental rat ovarian torsion model study, elevated serum IMA level was found to be associated with torsion response (Aran *et al.*, 2010).

A mouse model of intestinal ischemia reperfusion indicated that D-dimer was significantly elevated during the reperfusion phase. In acute intestinal ischemia, local intravascular coagulation is activated, thrombin formation and conversion of fibrinogen into fibrin increase,s and intravascular and extravascular fibrin accumulates. As a result, the levels of thrombin, antithrombin complex and D-dimer might increase (Schoots *et al.*, 2003). A similar mechanism might exist in ovarian torsion. A spectrum of ischemic changes due to ovarian torsion is noted in the ovary. The amount of damage depends on the extent of vascular compromise. First, the venous flow and lymphatic return are blocked, along with continued arterial perfusion of the ovary, leading to diffuse enlargement and edema of the ovarian parenchyma and often to peripheral follicular distension due to transudation of the fluid into the cysts. With further passage of time, continued edema and increased pressure on the twisted pedicle will cause venous

Downloaded from https://academic.oup.com/humrep/article-abstract/26/3/564/2914139 by Karadeniz Teknik University Library (KTU) user on 08 June 2020

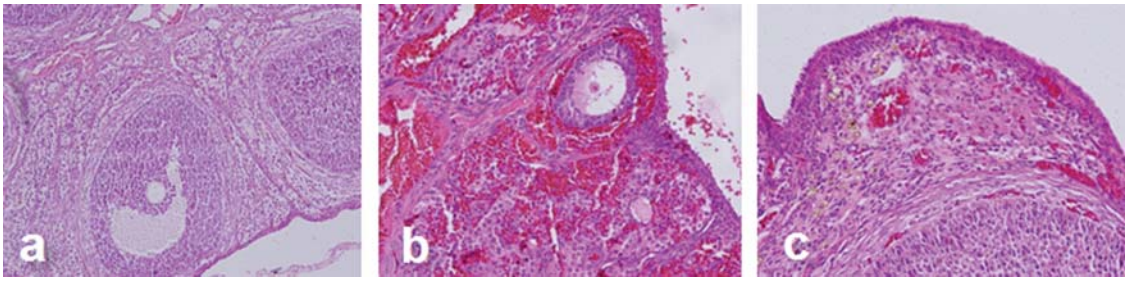

Figure 3 (**a**) Normal follicular development and no pathologic changes in control ovarian sections (original magnification: ×400; H&E stain), (**b**) In the torsion group, ovarian sections showed severe hemorrhage, vascular congestion, follicular cell degeneration and inflammatory cell infiltration (original magnification: ×400; H&E stain), (**c**) In the torsion group, ovarian sections showed extravascular and capillary fibrin deposition (original magnification: ×200; H&E stain).

occlusion followed by arterial thrombosis. Thus, we preferred to study a rat model to show elevated D-dimer levels in ovarian torsion.

Clinical studies of ovarian torsion have shown that early diagnosis is the key to a successful outcome (Cohen *et al.*, 2001; Daponte *et al.*, 2006; Aran *et al.*, 2010). Therefore, any new marker should have significantly increased concentrations immediately following the initiation of the clinical pathology that results in ovarian torsion. D-dimer can be an appropriate marker in this sense because it is the most rapidly elevating marker among fibrinogenolytic products: in bleeding esophageal varices, it increases significantly only 5 min after endoscopic embolization with thrombin (Suehiro and Koyama, 1991). The same increase can be anticipated after ovarian torsion, and this may aid in rapid diagnosis and treatment of ovarian torsion. We measured plasma D-dimer levels 2 h after the operation because various studies have shown that D-dimer increases within minutes after the onset of ischemia and remains elevated for 6–12 h (Acosta *et al.*, 2004; Kurt *et al.*, 2005; Altinyollar *et al.*, 2006).

The limitation of D-dimer testing in surgical practice is its low specificity in many conditions. Every surgical trauma and tissue injury or even i.m injection itself can activate coagulation and consequently the fibrinolytic system and cause elevated D-dimer values (Acosta *et al.*, 2004). In the present study, control group (sham-operated group) was designed in order to interpret the D-dimer test results in rats with torsed ovary. Thus, it was expected that mean D-dimer levels in both sham and torsion operation groups in the second post-operative hour were higher than that in the preoperative. But second post-operative hour mean D-dimer plasma levels in rats with torsed ovary were found statistically significantly higher than that in the pre-operative and second post-operative hour mean D-dimer plasma levels in sham operation group.

This study also had some limitations in terms of the model employed. This work was a case-controlled study, but it may not mimic typical ovarian torsion cases seen in clinical practice. However, the rarity of ovarian torsion and its subtle symptoms make a wider series of clinical studies difficult. The absence of serial blood measurement in this experimental model may be the limitation of our study. Serial blood measurements could alter rat hemodynamic status and affect plasma D-dimer levels; thus, we preferred not to use serial measurements.

The results obtained from the current experimental study suggest that the measurements of D-dimer might be used as a plasma marker in early detection and diagnosis of ovarian torsion. However, further clinical and experimental studies of a larger size are required to clearly confirm that an elevated D-dimer level is a useful adjunct in the early diagnosis of ovarian torsion.

Authors' roles

The study was designed by C.K., T.A. and S.G. Data were collected by C.K., T.A., S.G., S.C.K. and E.Y. Data were analyzed by C.K., T.A. and S.G., who also wrote the first draft of the manuscript. All authors participated in the finalization of the manuscript and read the final draft.

Conflict of interest: none declared.

References

Acosta S, Nilsson TK, Bjorck M. D-dimer testing in patients with suspected acute thromboembolic occlusion of the superior mesenteric artery. *Br J Surg* 2004;**91**:991–994.

Altinyollar H, Boyabatli M, Berberoglu U. D-dimer as a marker for early diagnosis of acute mesenteric ischemia. *Thromb Res* 2006; **117**:463–467.

Aran T, Guven S, Unsal MA, Alver A, Mentese A, Yulug E. Serum ischemia-modified albumin as a novel marker of ovarian torsion: an experimental study. *Eur J Obstet Gynecol Reprod Biol* 2010;**150**: 72–75.

Cohen SB, Wattiez A, Stockheim D, Seidman DS, Lidor AL, Mashiach S, Goldenberg M. The accuracy of serum interleukin-6 and tumour necrosis factor as markers for ovarian torsion. *Hum Reprod* 2001; **16**:2195–2197.

Daponte A, Pournaras S, Hadjichristodoulou C, Lialios G, Kallitsaris A, Maniatis AN, Messinis IE. Novel serum inflammatory markers in patients with adnexal mass who had surgery for ovarian torsion. *Fertil Steril* 2006;**85**:1469–1472.

Guven S, Muci E, Unsal MA, Yulug E, Alver A, Duman MK, Mentese A. The effects of carbon dioxide pneumoperitoneum on ovarian blood flow, oxidative stress markers, and morphology during laparoscopy: a rabbit model. *Fertil Steril* 2010;**93**:1327–1332.

Downloaded from https://academic.oup.com/humrep/article-abstract/26/3/564/2914139 by Karadeniz Teknik University Library (KTU) user on 08 June 2020

Hibbard LT. Adnexal torsion. *Am J Obstet Gynecol* 1985;**152**:456–461.
Hirano T, Akira S, Taga T, Kishimoto T. Biological and clinical aspects of interleukin 6. *Immunol Today* 1990;**11**:443–449.
Kurt Y, Akin ML, Demirbas S, Uluutku AH, Gulderen M, Avsar K, Celenk T. D-dimer in the early diagnosis of acute mesenteric ischemia secondary to arterial occlusion in rats. *Eur Surg Res* 2005; **37**:216–219.
Pena JE, Ufberg D, Cooney N, Denis AL. Usefulness of Doppler sonography in the diagnosis of ovarian torsion. *Fertil Steril* 2000;**73**:1047–1050.
Schoots IG, Levi M, Roossink EH, Bijlsma PB, van Gulik TM. Local intravascular coagulation and fibrin deposition on intestinal ischemia-reperfusion in rats. *Surgery* 2003;**133**:411–419.
Suehiro A, Koyama T. Clinical usefulness of the measurement of plasma D-dimer levels. *Rinsho Byori* 1991;**39**:694–700.

Downloaded from https://academic.oup.com/humrep/article-abstract/26/3/564/2914139 by Karadeniz Teknik University Library (KTU) user on 08 June 2020