LETTER TO THE EDITOR

Turk J Hematol 2026;43:302-304

Penile Plasmacytoma: A Rare Case

Penil Plazmositom: Nadir Bir Olgu

Özge Sönmez[1], Bircan Sönmez[2], Mehmet Sönmez[3]

[1]İstanbul University-Cerrahpaşa, Cerrahpaşa Faculty of Medicine, Department of Internal Medicine, İstanbul, Türkiye
[2]Karadeniz Technical University Faculty of Medicine, Department of Nuclear Medicine, Trabzon, Türkiye
[3]Karadeniz Technical University Faculty of Medicine, Department of Internal Medicine, Division of Hematology, Trabzon, Türkiye

To the Editor,

Solitary extramedullary plasmacytomas account for approximately 2%-5% of plasma cell neoplasms and are characterized by localized monoclonal plasma cell proliferation without clinical or laboratory features of multiple myeloma (MM). Bone marrow examination is usually normal or shows minimal clonal plasma cell infiltration [1,2]. Penile involvement is exceptionally rare [3]. Herein, we report a case of penile plasmacytoma and review the relevant literature.

A 70-year-old man with a history of hypertension and benign prostatic hyperplasia presented with a penile mass and urinary difficulties. Biopsy, initially performed for suspected penile carcinoma, revealed a plasma cell infiltrate with lambda light-chain restriction. Immunohistochemistry showed strong CD38 and CD138 positivity, with a Ki-67 proliferation index of approximately 70%. At diagnosis, serum creatinine was 1.22 mg/dL. Serum protein electrophoresis with immunofixation detected no monoclonal protein and the serum free light chain assay showed a normal kappa-to-lambda ratio. Bone marrow biopsy revealed no significant plasma cell infiltration. Positron emission tomography/computed tomography demonstrated marked penile infiltration without osteolytic lesions or other extramedullary disease (Figure 1).

Although the patient did not exhibit features of systemic involvement or bone marrow infiltration, a multidisciplinary decision involving the urology and hematology teams was made to initiate chemotherapy, considering his overall condition (Eastern Cooperative Oncology Group performance status: 2), advanced age, and the potential risk of surgical complication. Radiotherapy was not preferred due to the possible fibrosis risk. Surgery was considered high-risk but was to be reconsidered if the mass shrunk. Treatment with bortezomib, cyclophosphamide, and dexamethasone was started. The patient's voiding symptoms were initially relieved following treatment; however, the disease later progressed. Therapy was subsequently escalated to a carfilzomib-based regimen, followed by daratumumab and pomalidomide. Despite systemic treatment, post-renal obstruction led to worsening kidney function, necessitating a total penectomy, which was subsequently followed by adjuvant radiotherapy. The patient ultimately developed renal failure (creatinine: 3.85 mg/dL) due to post-renal obstruction and sepsis following interventional procedures on the kidney, and he died approximately 15 months after the initial diagnosis.

A literature search was conducted in PubMed using the term "penile plasmacytoma." Cases involving urethral plasmacytoma or other non-penile sites were excluded to focus specifically on lesions originating from penile tissue (Table 1).

We identified five reported cases, including one patient with a prior diagnosis of MM and another who subsequently developed MM [3,4,5,6,7]; thus, only three cases represented truly solitary penile plasmacytomas. All patients, typically elderly individuals, presented with a penile mass, which may mimic urological malignancies and delay diagnosis. Management included either plasma cell-directed therapy or surgical resection, although long-term follow-up data were largely unavailable. The paucity of follow-up data might underscore the absence of a standardized treatment approach and supports the need for individualized management strategies. Our patient received multiple lines of therapy; however, surgery was ultimately required due to post-renal obstruction. Although his voiding symptoms initially improved, similar to a previous report [7], they later worsened with disease progression. Previous reports describe temporary symptom relief or short-term disease control [3,7], whereas longer follow-up suggests recurrence and unfavorable outcomes [4].

Consequently, penile plasmacytoma is an extremely rare condition with no established treatment strategy. A multidisciplinary approach is essential for optimal management. Surgical intervention may be appropriate in selected patients, whereas systemic plasma cell-directed therapy may be considered when surgery is not feasible. Close monitoring is necessary due to the risk of disease progression and local

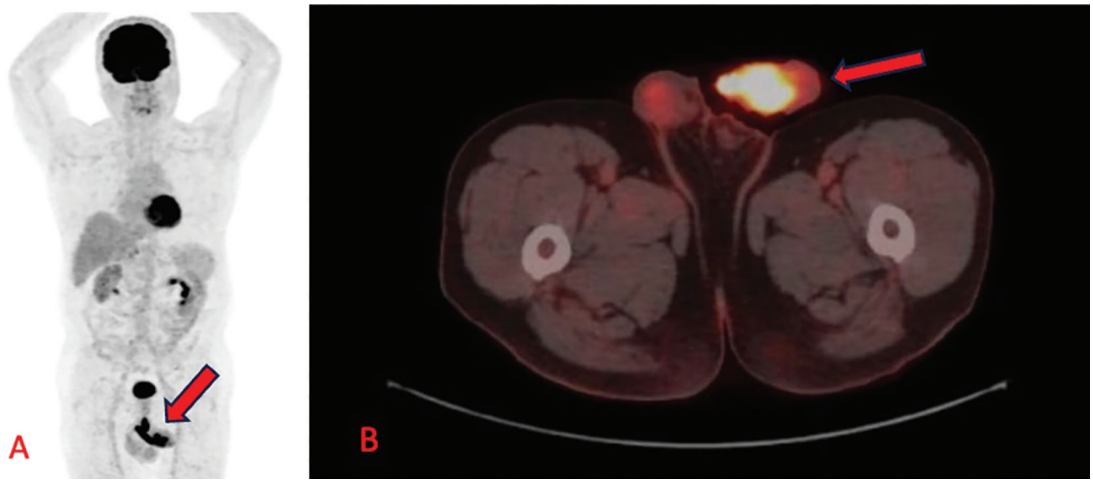

Figure 1. Positron emission tomography/computed tomography images of the patient in maximum intensity projection (A) and axial (B) planes demonstrate increased fluorodeoxyglucose (FDG) uptake in a lesion invading the penis (maximum standardized uptake value: 12.13). Increased FDG uptake is also observed in the dilated urethra proximal to the lesion, likely secondary to urinary stasis (indicated by red arrows).

Table 1. Summary of reported cases of penile plasmacytoma.

Authors	Year	Age	Symptom	Underlying MM	Treatment	Outcome
Coelho et al. [4]	2023	77	Painful penile mass	Relapsed extramedullary penile plasmacytoma 14 months after initial MM treatment	Lenalidomide-dexamethasone followed by external beam radiation therapy (30 Gy)	Disease recurred after 18 cycles of treatment, ultimately resulting in death due to progressive disease
Wang et al. [3]	2013	64	Palpable penile mass	No underlying MM	Surgical resection	No evidence of relapse or development of MM at 2 months after surgery
Chen et al. [5]	2024	72	Painless penile mass	No underlying MM	NA	NA
Scarberry et al. [6]	2014	90	Penile mass	No underlying MM	Surgical resection	NA
Orzechowski et al. [7]	2024	88	Palpable penile mass	Diagnosed with MM following the detection of penile plasmacytoma	Lenalidomide, bortezomib, and dexamethasone treatment	Improvement in voiding symptoms after 3 cycles of treatment

MM: Multiple myeloma; NA: not available.

complications, including post-renal kidney injury. Despite multimodal treatment approaches, long-term outcomes may remain unfavorable in some patients.

Keywords: Penile plasmacytoma, Challenging and rare cases, Mini literature review

Anahtar Sözcükler: Penil plazmasitom, Nadir ve zor olgular, Mini literatür taraması

Ethics

Informed Consent: Written informed consent was obtained from the patient for the publication of this case report and the accompanying images.

Footnotes

Authorship Contributions

Surgical and Medical Practices: M.S., B.S.; Concept: M.S.; Design: M.S.; Data Collection and Processing: M.S., B.S.; Analysis or Interpretation: Ö.S.; Literature Search: Ö.S.; Writing: Ö.S., M.S.

Conflict of Interest: No conflict of interest was declared by the authors.

Financial Disclosure: The authors declared that this study received no financial support.

References

1. Charalampous C, Claveau JS, Kapoor P, Binder M, Buadi FK, Cook J, Dingli D, Dispenzieri A, Fonder AL, Gertz MA, Gonsalves W, Hayman SR, Hobbs MA, Hwa YL, Kourelis T, Lacy MQ, Leung N, Lin Y, Warsame R, Kyle RA, Rajkumar SV, Kumar SK. Solitary plasmacytoma: single-institution experience, and systematic review and meta-analysis of clinical outcomes. Blood Adv. 2025;9:1559-1570.
2. Grammatico S, Scalzulli E, Petrucci MT. Solitary plasmacytoma. Mediterr J Hematol Infect Dis. 2017;9:e2017052.
3. Wang Y, Li HY, Liang TT, Han YP, Wang XJ, Wei X, Fan L, Wang WH. Primary extramedullary plasmacytoma of the penis: a case report. Jpn J Clin Oncol. 2013;43:1030-1033.
4. Coelho H, Badior M, Pinto P, Ribeiro A, Tavares M. Multiple myeloma relapse as extramedullary plasmacytoma of the penis. Ann Hematol. 2023;102:3649-3651.
5. Chen X, Chen G, Li Q, Fu Z. 18F-FDG PET/CT in solitary extramedullary plasmacytoma of the penis. Clin Nucl Med. 2024;49:680-682.
6. Scarberry K, Jegalian A, Valent J, Wood HM. Solitary extramedullary plasmacytoma of the penis. Urol Ann. 2014;6:242-243.
7. Orzechowski M, Kowal P, Ratajczyk K, Borucki M, Blaszczyszyn K. Extramedullary plasmacytoma of the penis as a first manifestation of multiple myeloma: a case report. Urol Int. 2024;108:168-171.

Address for Correspondence/Yazışma Adresi: Prof. Mehmet Sönmez, M.D., Karadeniz Technical University Faculty of Medicine, Department of Internal Medicine, Division of Hematology, Trabzon, Türkiye
E-mail: mesonmez@yahoo.com **ORCID:** orcid.org/0000-0002-2176-4371

Received/Geliş tarihi: March 7, 2026
Accepted/Kabul tarihi: April 8, 2026
Epub: April 8, 2026
DOI: 10.4274/tjh.galenos.2026.53244

©Copyright 2026 by Turkish Society of Hematology Turkish Journal of Hematology, Published by Galenos Publishing House.
Licensed under a Creative Commons Attribution-NonCommercial (CC BY-NC-ND) 4.0 International License.